

Percutaneous Collagen Induction Therapy: An Alternative Treatment for Scars, Wrinkles, and Skin Laxity

Matthias C. Aust, M.D.

Des Fernandes, M.D.

Perikles Kolokythas, M.D.

Hilton M. Kaplan, M.D.

Peter M. Vogt, M.D.

Hannover, Germany; Cape Town, South Africa; and Los Angeles, Calif.

Background: Skin laxity, rhytides, and photoaging are generally treated by ablative procedures that injure or destroy the epidermis and its basement membrane, at least in the beginning, and subsequently lead to fibrosis of the papillary dermis. The ideal treatment would be to preserve the epidermis and promote normal collagen and elastin formation in the dermis. Percutaneous collagen induction takes us closer to this ideal.

Methods: The authors performed a retrospective analysis of 480 patients in South Africa and Germany with fine wrinkles, lax skin, scarring, and stretch marks treated with percutaneous collagen induction using the Medical Roll-CIT to produce tighter, smoother skin. Most patients had only one treatment, but some have had as many as four treatments. Patients were prepared with topical vitamin A and C cosmetic creams for a minimum of 4 weeks preoperatively.

Results: On average, patients in Germany rated their improvement between 60 and 80 percent better than before the treatment. Histologic examination was carried out in 20 patients and showed a considerable increase in collagen and elastin deposition at 6 months postoperatively. The epidermis demonstrated 40 percent thickening of stratum spinosum and normal rete ridges at 1 year postoperatively.

Conclusions: Percutaneous collagen induction was started in 1997 and has proved to be a simple and fast method for safely treating wrinkles and scars. As opposed to ablative laser treatments, the epidermis remains intact and is not damaged. For this reason, the procedure can be repeated safely and is also suited to regions where laser treatments and deep peels cannot be performed. (*Plast. Reconstr. Surg.* 121: 1421, 2008.)

As the demand for less invasive, highly effective cosmetic procedures grows, plastic surgeons must explore and develop new treatment options. Patients request skin treatments to rejuvenate photoaging, abnormal pigmentation or vascularity, textural problems, rhytides, and laxity caused by chronological aging. We have numerous methods today to tighten skin, such as laser resurfacing and deep peeling.¹⁻⁵ However, these treatments are ablative and tighten the skin

From the Klinik für Plastische, Hand- und Wiederherstellungschirurgie, Medizinische Hochschule Hannover; Department of Plastic and Reconstructive Surgery, Groote Schuur Hospital; and Department of Biomedical Engineering, University of Southern California.

Received for publication November 17, 2006; accepted February 28, 2007.

Copyright ©2008 by the American Society of Plastic Surgeons

DOI: 10.1097/01.prs.0000304612.72899.02

Disclosures: Dr. Des Fernandes is employed as the senior medical consultant for Environ Skin Care Pty. Ltd. (South Africa), whose products were used by all the patients in this report. He does not own any equity in Environ Skin Care Pty. Ltd. The Roll-Cit products are made by Vivida Closed Corporation. Dr. Des Fernandes is a shareholder in Vivida Closed Corporation and is employed by Vivida as a medical consultant. Dr. Matthias Aust is the medical consultant for Care Concept, distributors for Environ Skin Care Products and Roll-Cit in Germany. Dr. Hilton Kaplan is the medical advisor to DermoGenesis, USA, a U.S. distributor of Environ. Prof. Vogt and Dr. Kolokythas have no sources of funds supporting the work and no financial interest in any of the products, devices, or drugs mentioned in this article.

or lighten scars because generally they destroy the epidermis and, very importantly, its basement membrane, which is replaced by an epidermis that no longer has dermal papillae and, at least in the beginning, is thinner than before.^{6–8} The destruction of the epidermis initiates an inflammatory response that stimulates fibroblasts to produce thick bundles of scar collagen in parallel orientation rather than the normal lattice network of collagen found in normal skin.^{9,10} The skin becomes more sensitive to photodamage and may also develop dyschromias.⁸

As far as scars are concerned, these treatments all work on the same principle as dermabrasion: the level of the normal skin is taken down closer to the level of the offending scar, which does not have normal epidermis.^{11–13} The ideal treatment would be to do exactly the opposite: by instead improving the scar quality and building up the scarred tissue to the level of the normal skin. On account of the complications of resurfacing lasers and deep peels, other modalities such as fractionated laser, radiofrequency heat, superficial repetitive peels, and intense pulsed light have become more popular.¹⁴

Furthermore, patients are now demanding less aggressive treatments. This is borne out by statistics from the American Society of Plastic Surgeons that demonstrate a 43 percent increase in minimally invasive surgical interventions between 2000 and 2005, compared with only a 16 percent increase for invasive cosmetic surgical interventions.¹⁵ Over time, minimally invasive surgical procedures will outnumber traditional open surgical procedures, with the market for related minimally invasive surgical devices set to soar from its current size in Europe of \$779 million to \$1164 million in 2011¹⁵ (in U.S. dollars).

We have learned in recent years that transforming growth factor (TGF)- β plays an enormous role in the first 48 hours of scar formation. Whereas TGF- β 1 and TGF- β 2 promote scar collagen, TGF- β 3 seems to promote regeneration and scarless wound healing with a normal collagen lattice.^{10,16,17} The ideal treatment of wrinkles and scars should be to promote regeneration rather than cicatrization, and this could offer our patients the result that they are hoping for.

We believe that percutaneous collagen induction brings us closer to this ideal of regeneration, even though we still have far to go. Percutaneous collagen induction creates thousands of microclefts through the epidermis into the papillary dermis. These tiny wounds in the papillary dermis create a virtually confluent zone of superficial

bleeding that is a powerful stimulus to initiate the normal process of wound healing. Because it is nonablative, percutaneous collagen induction can be performed on the face and body, on all skin types, without concern for aesthetic unit boundaries, and, very importantly, without predisposing the patient to hyperpigmentation. For percutaneous collagen induction, we have used the Environ Medical Roll-CIT (Vivida-SA cc, Cape Town, South Africa), which is a sterile plastic cylinder with needles protruding between 1 and 3 mm from the surface to roll vigorously over the skin (Fig. 1).

PATIENTS AND METHODS

This is a retrospective analysis of patients operated on between 1997 and 2006 in South Africa and Germany. These patients underwent percutaneous collagen induction for fine wrinkles, lax skin, scarring, and stretch marks. The skin of all 480 patients was prepared preoperatively for at least 1 month with vitamin A (retinyl palmitate) cream and vitamin C cream [ascorbyl tetra-isopalmitate (Environ Original and C-Boost; Environ Skin Care, Pty. Ltd., Cape Town, South Africa)] applied topically twice daily.

Demographic Data

The demographic data of 480 patients are listed in Table 1. Four hundred of the patients were women and 80 were men (female-to-male ratio, 5:1). The average age was 49 ± 15.5 years (range, 18 to 74 years). The average time to surgery (duration from consultation) was 3 ± 15.5 months (range, 1 to 12 months). This is relevant because it represents the duration over which pa-

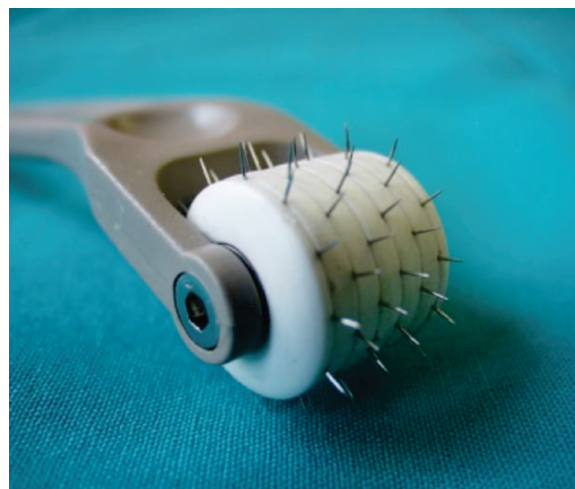

Fig. 1. The Environ Medical Roll-CIT (made by Vivida-SA cc, Renaissance Body Science Institute, Cape Town, South Africa).

Table 1. Demographic Data

Group	Wrinkles	Scars	Lax Skin	Average
No. (<i>n</i> = 480)	350	72	58	
Female/male	300/50	55/17	45/13	5/1
Age, years	51.9 ± 12.1	41.7 ± 10.3	49.7 ± 10.1	49 ± 15.5
Time from consultation to operation, months	2.9 ± 1.3	3.1 ± 1.4	3.2 ± 1.6	3 ± 15.5

tients can pretreat their skin with vitamins A and C. Twenty-eight of the 480 patients had been treated previously with chemical peeling or dermabrasion elsewhere.

Method

Orentreich and Fernandes independently described “subcision” or dermal needling.^{18,19} This involves pricking the skin and then scarifying the dermis with a needle to build up connective tissue under scars and wrinkles. However, this technique could not be used over large surface areas. Camirand used a tattoo gun to treat scars with “needle abrasion.”²⁰ The fundamental similarity of these different techniques is that the needles disrupt the old collagen structures that connect the scar with the upper dermis. The associated trauma induces the normal wound-healing inflammatory cascade, and the scar collagen that is broken down is replaced with new collagen under the epidermis. Based on these principles, Fernandes developed a new technology, percutaneous collagen induction, to initiate the natural posttraumatic inflammatory cascade by rolling needles vertically, horizontally, and diagonally with pressure over the treated area²¹ (Figs. 2 and 3). These needle pricks lead to thousands of microwounds in the dermis. For percutaneous collagen induction, the skin was anesthetized with a topical anesthetic cream or

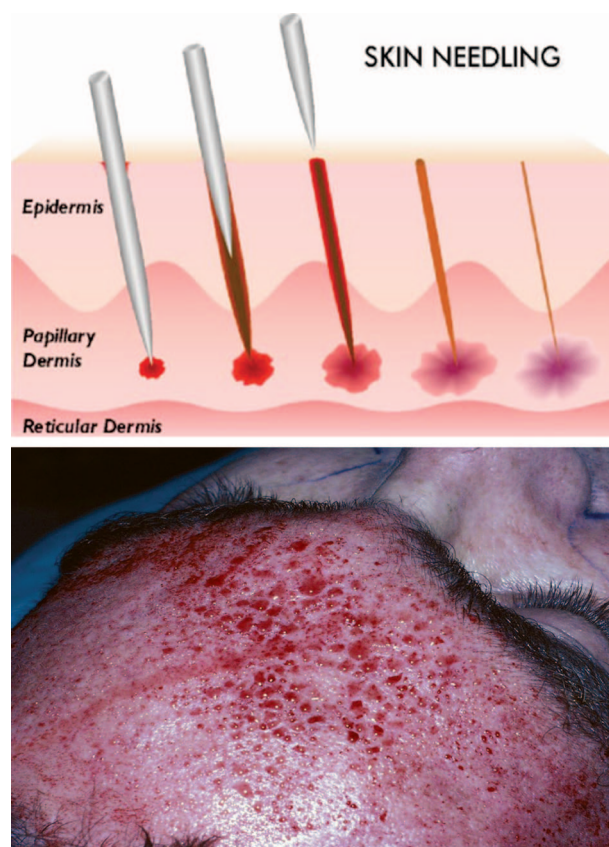


Fig. 3. (Above) Schematic image of the procedure. (Below) Intraoperative view of a needled forehead.

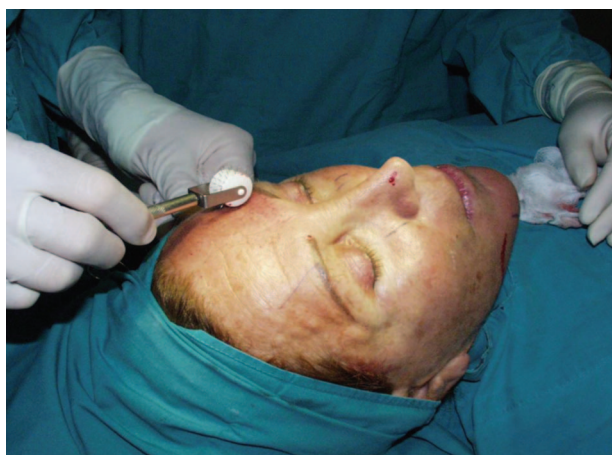

Fig. 2. The operative procedure.

with regional nerve blocks and/or infiltration of local anesthetic and conscious sedation (where large or sensitive areas are being treated), or general anesthesia.

Histology

Histology was carried out with 3-mm punch biopsies, to compare preoperative collagen and elastin to that obtained postoperatively, both qualitatively and quantitatively, using van Gieson, elastica, and hematoxylin and eosin stains (Figs. 4 and 5).

Indications for Percutaneous Collagen Induction

Patients with indications for percutaneous collagen induction were divided into three groups:

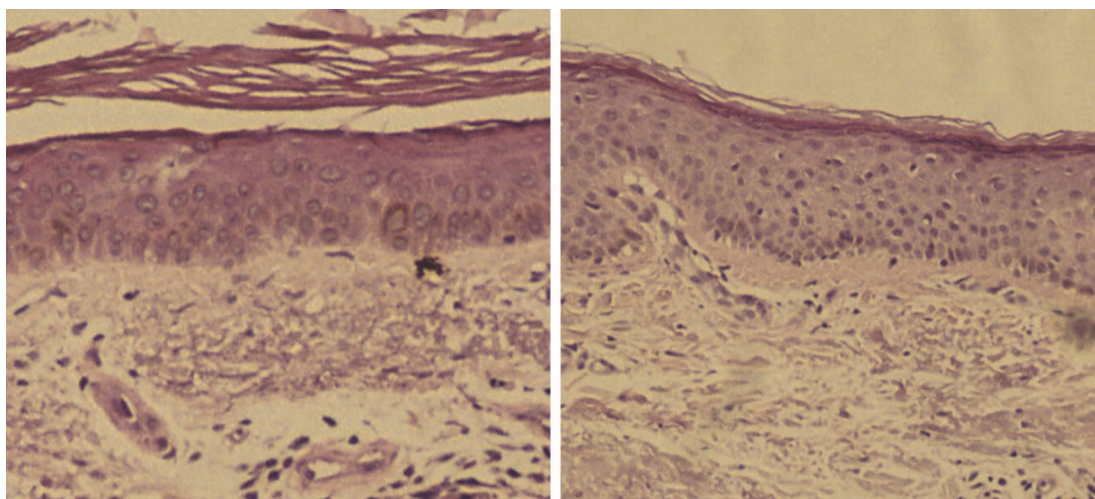


Fig. 4. (Left) Preoperative histologic photomicrograph of the abdomen. (Right) Histologic photomicrograph of the abdomen obtained 1 year postoperatively. Hematoxylin and eosin staining shows that, at 1 year postoperatively, the stratum corneum is normal and the epidermis shows no signs of any abnormality and is of normal thickness, with regular rete peg formation.

fine wrinkles (face); scarring (acne, varicella, burns); and stretch marks (striae) or lax skin (face, abdomen, arms, legs, and thighs).

Group I: Wrinkles

Group I consisted of patients with fine wrinkles ($n = 350$) (Figs. 6 and 7).

Group II: Scarring

Group II consisted of patients with acne or burn scars ($n = 72$) (Fig. 8).

Group III: Lax Skin/Striae

Group III consisted of patients with stretch marks or lax skin of the abdomen or arms ($n = 58$) (Figs. 9 and 10).

Postoperative Care

Immediately after percutaneous collagen induction, the area is swollen, with superficial bruising. After the initial bleeding stops within a few minutes, there is a serous ooze, which stops within the first few hours after the operation. To absorb the bleeding and serous ooze, the treated area should be covered with cool, damp swabs that are periodically replaced for the first 2 hours after the operation. The skin is finally washed with a tea tree oil-based cleanser and the vitamin A and C regimen starts immediately. The patient is instructed to wash the face thoroughly again when they return home.

Patients usually do not require postoperative analgesia if the procedure has been performed under local anesthesia. When the procedure has been performed under general anesthesia without any local/topical anesthetic, the patient may com-

plain of burning for the first hour postoperatively, so it is wise to administer an analgesic at the end. The edema can be quite significant when needling has been performed but starts resolving from the second day postoperatively, and by the fourth or fifth day there is usually only mild erythema remaining. Patients are usually able to return to normal daily life by the seventh day. Topical vitamin A and C both maximize initial release of growth factors and stimulate collagen production.²²⁻²⁶

Advantages and Disadvantages

Major advantages of percutaneous collagen induction are that the patients have no open wound and consequently require only a short healing phase. Because the epidermis and stratum corneum are only clefted and are never removed, there is no exposure to air and no risk of photosensitivity or any postinflammatory hyperpigmentation or hypopigmentation. Disadvantages that the authors see are blood exposure of the surgeon, the need for complete anesthesia of the skin when performing needling, unsightly swelling and bruising for the first 4 to 7 days, and that the final result takes longer than with laser resurfacing (new collagen continues to be laid down for approximately 3 months).^{19,21}

Statistical Analysis

Statistical analysis was performed using the chi-square test. Significance was accepted at a level of $p \leq 0.05$.

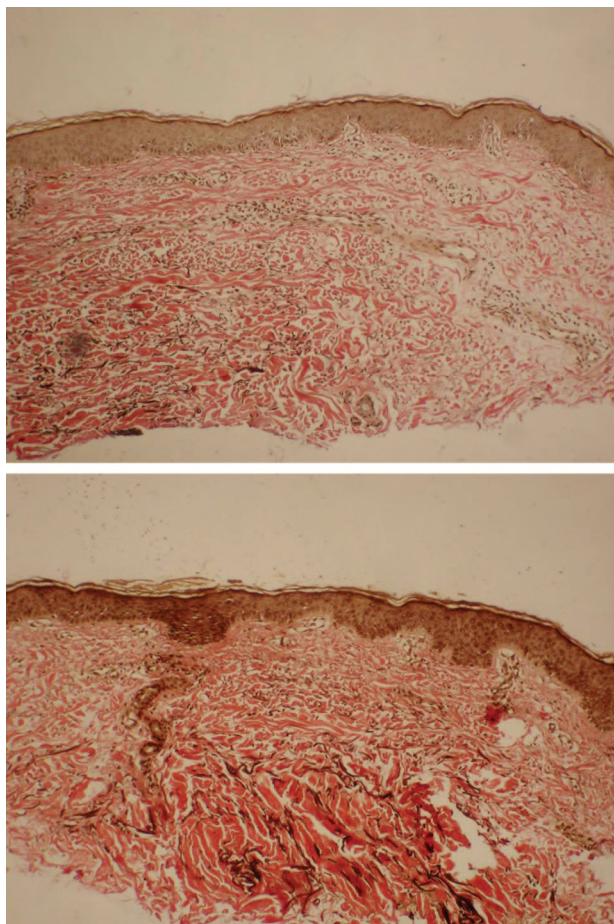


Fig. 5. (Above) Preoperative histologic photomicrograph of the face. (Below) Histologic photomicrograph of the face obtained 6 months postoperatively. Van Gieson stain shows that, 6 months after needling, there is a considerable increase in collagen and elastin deposition, and the collagen appears not to have been laid down in parallel bundles but is rather in the normal lattice pattern.

RESULTS

Postoperatively, all treated patients were able to return to normal daily life after 1 week. No patient required postoperative analgesia, and all continued to apply vitamins A and C twice daily on an ongoing basis.

Histology

Van Gieson staining showed a considerable increase in collagen deposition at 6 months postoperatively. The collagen also appears to have been laid down in a normal lattice pattern, rather than in parallel bundles as seen in scar tissue. Similarly, elastica staining showed an increase in elastin at 6 months postoperatively. Hematoxylin and eosin staining demonstrated a normal stratum

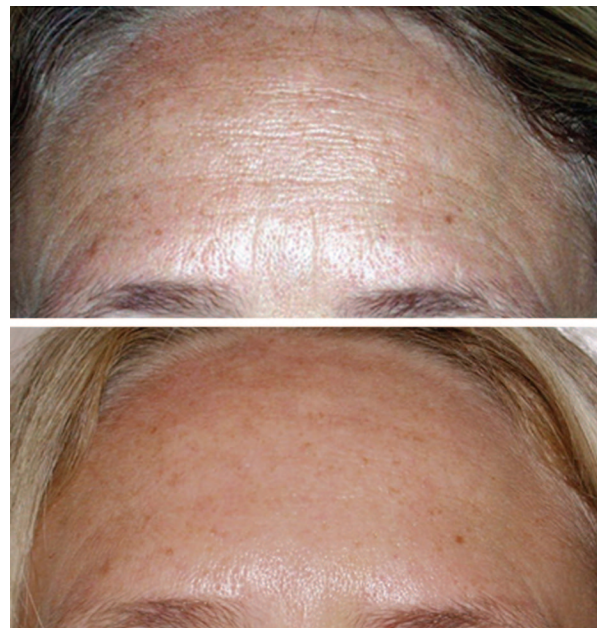

Fig. 6. A 47-year-old woman with wrinkles of the forehead preoperatively (above) and 1 year postoperatively (below).

corneum, thickened epidermis (40 percent thickening of the stratum granulosum), and normal rete ridges at 1 year postoperatively (Figs. 4, left, and 5, below).

Patient Satisfaction

In 50 patients treated in Germany (15 cases with scars and stretch marks and 35 with wrinkles), patient satisfaction was evaluated prospectively before percutaneous collagen induction and 12 months postoperatively by the patient themselves using a visual analogue scale (0 = absolutely dissatisfied and 10 = completely satisfied). In group I (wrinkles), the average preoperative score was 4.5 (range, 2 to 5), which improved significantly to 8.5 (range, 7 to 10) postoperatively. Group II (scarring) also improved significantly from 3.0 (range, 1 to 5) to 7.5 (range, 7 to 8); and so did group III (lax skin/striae), from 3.5 (range, 2 to 5) to 8.0 (range, 7 to 9) (Table 2).

In the 15 cases with scars and stretch marks treated in Germany, the Vancouver Scar Scale was compared with two reliable, objective, and universal methods for assessing scars: the Vancouver Scar Scale, and the Patient and Observer Scar Assessment Scales. The Vancouver Scar Scale has been described to provide a descriptive terminology for the comparison of scars and assessing the results of treatments.²⁷⁻²⁹ It considers four parameters: vascularity, height (thickness), pliability, and pigmentation. Each variable is scored for severity

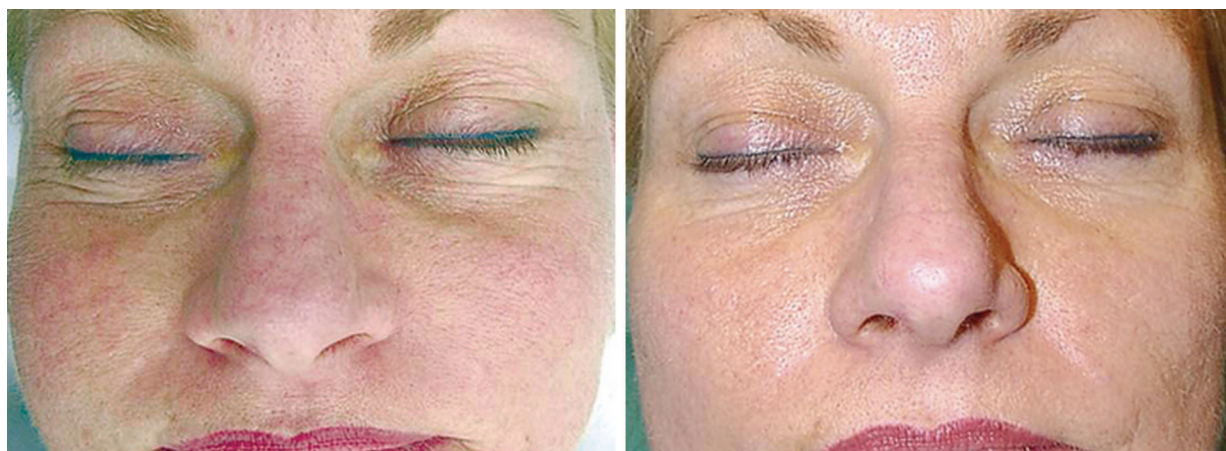

Fig. 7. A 41-year-old woman with wrinkles of the face preoperatively (*left*) and 9 months postoperatively (*right*).

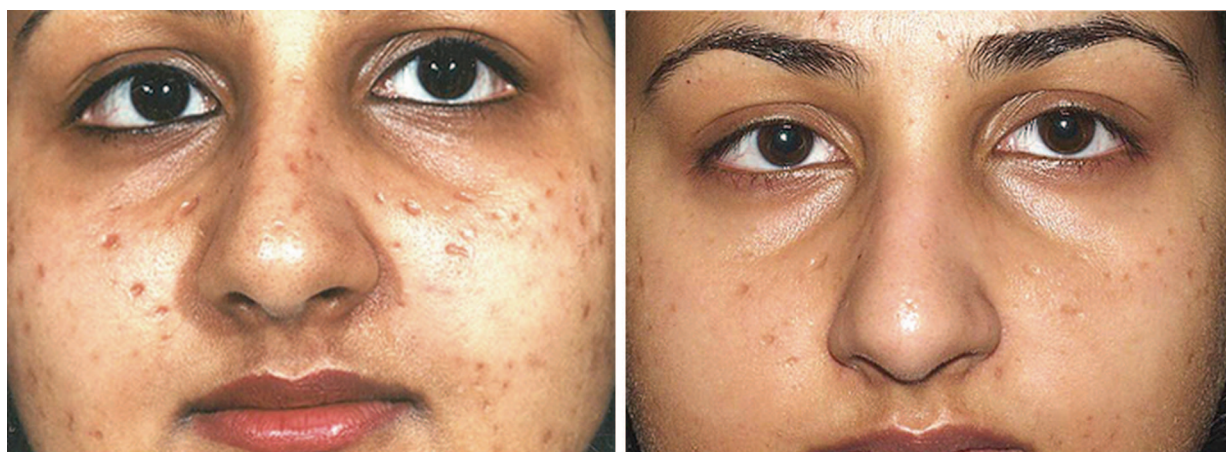

Fig. 8. A 24-year-old woman with chickenpox scars preoperatively (*left*) and 1 year postoperatively (*right*).

between 0 (normal skin) and 4 (most severe) to give a total score of between 0 and 16 (where 0 reflects normal skin).^{27–29} The assessments were carried out by two independent observers who regularly treat scarred patients.

The Patient and Observer Scar Assessment Scales consists of two scales: the patient scale, which considers six parameters (color, pliability, thickness, relief, itching, and pain); and the observer scale, which considers five parameters (vascularization, pliability, pigmentation, thickness, and relief). Each parameter is scored from 0 to 10, where 10 reflects the worst severity. At 12 months after percutaneous collagen induction, each patient and the two independent observers completed the observer and the patient scales for that patient's scars.

In these 15 patients with scarring, the average preoperative Vancouver Scar Scale score was 7.5 ± 11.5 (range, 4 to 11), which improved to 4.8 ± 15.5 (range, 1 to 6) at 1 year after percutaneous collagen induction therapy. The Pa-

tient and Observer Scar Assessment Scale scores improved on average from 27 ± 13.5 (range, 14 to 38) preoperatively to 19 ± 11.5 (range, 14 to 25) at 1 year after percutaneous collagen induction therapy (Table 3). Postoperatively, no patients experienced any photosensitivity or developed any postinflammatory hyperpigmentation or hypopigmentation.

Limitations and Complications

Limitations include the inadequate pretreatment with vitamin A of some patients, any active skin processes (e.g., active acne), and unrealistic expectations of some patients. Some patients came for a second or third treatment to improve the outcome, but as far as the authors know, no treated patient underwent any open surgical procedure because the percutaneous collagen induction did not meet their expectation.

Two patients developed herpes simplex infection after a full-face needling. These infections

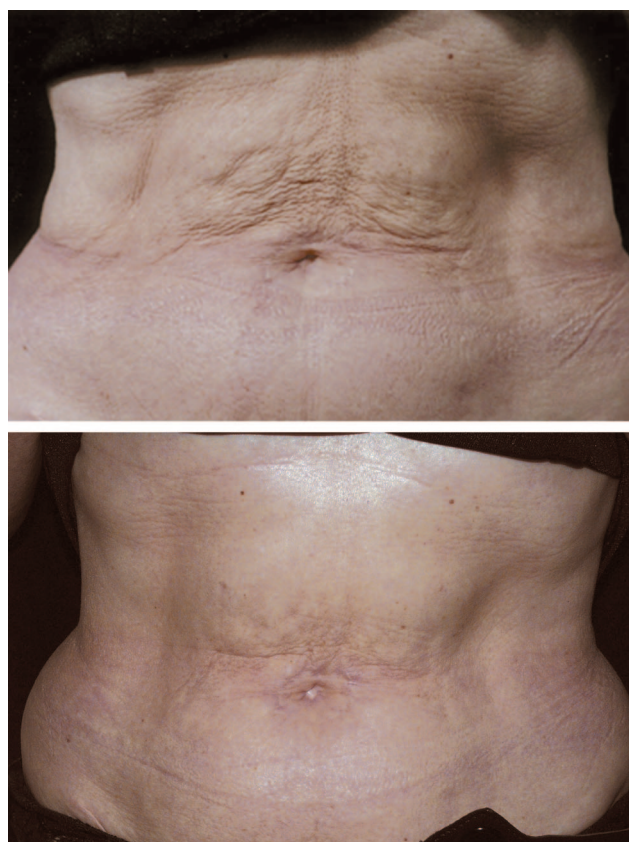


Fig. 9. A 51-year-old woman with lax skin abdomen preoperatively (*above*) and 1 year postoperatively (*below*).

were treated successfully with acyclovir. Some patients reported swelling and bruising for up to 7 to 10 days. No patients reported scarring, hypopigmentation or hyperpigmentation, or photosensitivity postoperatively.

DISCUSSION

Rationale for Using Topical Vitamins A and C

The necessity for using vitamins A and C for percutaneous collagen induction has been well described by Fernandes.¹⁹ Vitamin A, a retinoic acid, is an essential vitamin (actually a hormone) for skin. It expresses its influence on 400 to 1000 genes that control proliferation and differentiation of all the major cells in the epidermis and dermis.^{30–38} It may control the release of TGF- β 3 in preference to TGF- β 1 and TGF- β 2 because, in general, retinoic acid seems to favor the development of a regenerative lattice-patterned collagen network rather than the parallel deposition of scar collagen found with cicatrization.^{39,40} Retinyl esters are the main form of vitamin A in the skin,^{19,41,42} and for these reasons, we have elected to apply vitamin A in its ester forms (retinyl palmi-

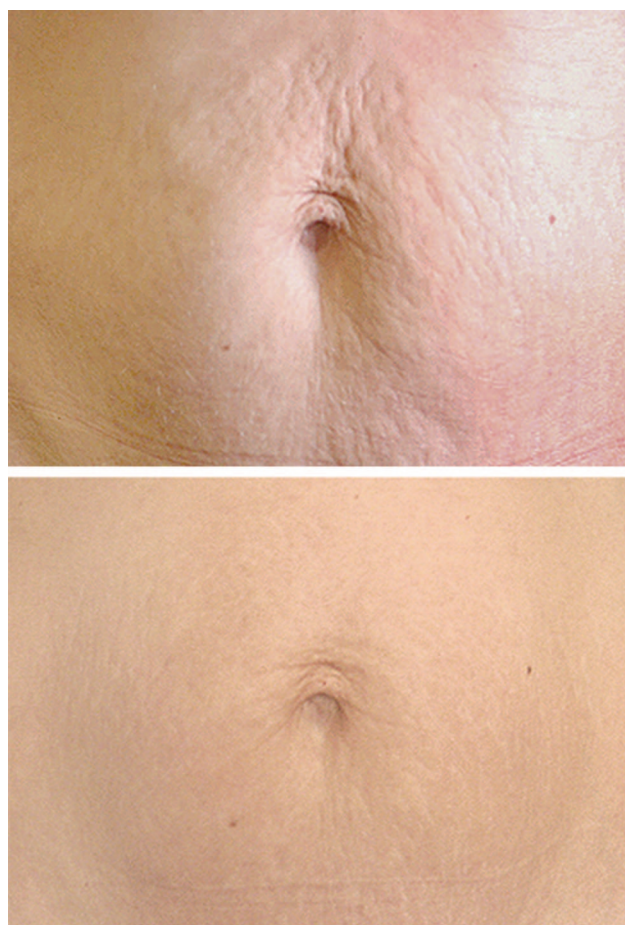


Fig. 10. A 39-year-old woman with striae abdominales after three pregnancies preoperatively (*above*) and 6 months postoperatively (*below*).

Table 2. Patient Satisfaction: Visual Analogue Scale

	Group		
	Wrinkles	Scars	Lax Skin
Preoperative score	4.5	3.0	3.5
Postoperative score	8.5	7.5	8.5
<i>p</i>	≤ 0.005	≤ 0.005	≤ 0.005

Table 3. Patient Satisfaction: VSS and POSAS Scores*

	VSS	POSAS
No.	72	72
Preoperative score	7.5	27
Postoperative score	4.8	19
<i>p</i>	≤ 0.005	≤ 0.005

*VSS, Vancouver Scar Scale; POSAS, Patient and Observer Scar Assessment Scales.

tate and retinyl acetate), with little use of retinol or retinoic acid directly.

Vitamin C is also essential for the production of normal collagen.^{19,41} Percutaneous collagen in-

duction and vitamin A switch on the fibroblasts to produce collagen and therefore increase the need for vitamin C.

Normal Stimulation of Collagen Production

Percutaneous collagen induction aims to stimulate collagen production by using the normal chemical cascade that ensues after any trauma. There are three phases in the body's wound-healing process, which follow each other in a predictable fashion. This has been well described in *The Biology of the Skin* by Falabella and Falanga.⁴³ Platelets and eventually neutrophils release growth factors such as TGF- α , TGF- β , platelet-derived growth factor, connective tissue activating protein III, connective tissue growth factor, and others that work in concert to increase the production of intercellular matrix.

Monocytes then also produce growth factors to increase the production of collagen III, elastin, glycosaminoglycans, and so forth. Approximately 5 days after skin injury, a fibronectin matrix forms with an alignment of the fibroblasts that determines the deposition of collagen. Eventually, collagen III is converted into collagen I, which remains for 5 to 7 years. With this conversion, the collagen tightens naturally over a few months. Percutaneous collagen induction causes even further tightening of lax skin and smoothening of scars and wrinkles several weeks or even months after the injury.⁴⁴

During the usual conditions of wound healing, scar tissue is formed with minimal regeneration of normal tissue. We hypothesize that the controlled wound milieu created during percutaneous collagen induction, by minimizing the usual stresses such as exposure to air, infection, mechanical tension, and so forth, may take us closer to regenerative healing. We also believe that our results support our hypothesis.

CONCLUSIONS

Finally, we should question why we destroy the epidermis to achieve smooth skin. The epidermis is a complex, highly specialized protective layer, even though it is only approximately 0.2 mm thick. We should only destroy the epidermis for medical reasons, never for aesthetic ones. The first step to a healthier skin is to restore the natural levels of photosensitive vitamins (e.g., vitamins A and B₁₂), antioxidants (e.g., vitamins C and E), and carotenoids, which all become depleted after exposure of the skin to light each day.^{45,46}

Although structural changes to the face and body may be achieved with surgery (e.g., face lifts), true rejuvenation also depends largely on youthful appearing skin. Percutaneous collagen induction offers an antiaging modality to rejuvenate and improve the appearance of old skin. We can now improve our patients' skin from the inside out and not just from the surface. Experience has shown that percutaneous collagen induction works optimally when combined with a scientific skin care program to restore a youthful appearance. In addition, percutaneous collagen induction has proven to be very effective in minimizing acne and burn scars, by promoting the replacement of scar collagen with normal collagen and the reduction of depressed and contracted scars.

Since the introduction of percutaneous collagen induction therapy in 1997, it has evolved into a simple and fast method for safely treating wrinkles and scars and producing smoothness. As opposed to ablative laser treatments, the epidermis remains intact and is not damaged. For this reason, the procedure can be repeated safely and is also suited to regions where laser treatments and deep peels cannot be performed.

Matthias C. Aust, M.D.

Klinik für Plastische, Hand- und
Wiederherstellungschirurgie
Hochschule Hannover
Carl-Neuberg Straße 1
Hannover 30625, Germany
aust_matthias@gmx.de

REFERENCES

1. Manolins, E. N. In vivo effect of carbon dioxide laser-skin resurfacing and mechanical abrasion on the skin's microbial flora in an animal model. *Dermatol. Surg.* 32: 359, 2006.
2. Atkins, D. Skin rejuvenation in facial surgery. *Facial Plast. Surg.* 22: 129, 2006.
3. Landau, M. Advances in deep chemical peels. *Dermatol. Nurs.* 17: 438, 2005.
4. Hegedus, F. Non-surgical treatment modalities of facial photodamage: Practical knowledge for the oral and maxillofacial professional. *Int. J. Oral Maxillofac. Surg.* 35: 389, 2006.
5. Fulton, J. E. Chemical peels: Their place within the range of resurfacing techniques. *Am. J. Clin. Dermatol.* 5: 179, 2004.
6. Roy, D. Ablative facial resurfacing. *Dermatol. Clin.* 23: 549, 2005.
7. Ross, E. V. Comparison of carbon dioxide laser, erbium: YAG laser, dermabrasion, and dermatome: A study of thermal damage, wound contraction, and wound healing in a live pig model. Implications for skin resurfacing. *J. Am. Acad. Dermatol.* 42: 92, 2000.
8. Bernstein, L. J. The short- and long-term side effects of carbon dioxide laser resurfacing. *Dermatol. Surg.* 23: 519, 1997.

9. Laws, R. A. Alabaster skin after carbon dioxide laser resurfacing with histologic correlation. *Dermatol. Surg.* 24: 633, 1998.
10. Rawlins, J. M. Quantifying collagen type in mature burn scars: A novel approach using histology and digital image analysis. *J. Burn Care Res.* 27: 60, 2006.
11. Kauvar, A. N. Histology of laser resurfacing. *Dermatol. Clin.* 15: 459, 1997.
12. Kang, D. H. Laser resurfacing of smallpox scars. *Plast. Reconstr. Surg.* 116: 259, 2005.
13. Ayhan, S. Combined chemical peeling and dermabrasion for deep acne and posttraumatic scars as well as aging face. *Plast. Reconstr. Surg.* 102: 1238, 1998.
14. Sadick, N. S. Combination radiofrequency and light energies: Electro-optical synergy technology in esthetic medicine. *Dermatol. Surg.* 31: 1211, 2005.
15. Data from the Medical Devices News Article: August 3, 2005. Available at: www.medicalnews.com. Accessed September 2005.
16. Ferguson, M. W. Scar-free healing: From embryonic mechanisms to adult therapeutic intervention. *Philos. Trans. R. Soc. Lond. B Biol. Sci.* 359: 839, 2004.
17. Bandyopadhyay, B. A "traffic control" role for TGF β 3: Orchestrating dermal and epidermal cell motility during wound healing. *J. Cell Biol.* 172: 1093, 2006.
18. Orentreich, D. S. Subcutaneous incisionless (subcision) surgery for the correction of depressed scars and wrinkles. *Dermatol. Surg.* 6: 543, 1995.
19. Fernandes, D. Percutaneous collagen induction: An alternative to laser resurfacing. *Aesthetic Surg. J.* 22: 315, 2002.
20. Camirand, A. Needle dermabrasion. *Aesthetic Plast. Surg.* 21: 48, 1997.
21. Fernandes, D. Skin needling as an alternative to laser. Presented at the International Confederation for Plastic, Reconstructive, and Aesthetic Surgery Conference, San Francisco, Calif., June 26–30, 1999.
22. Yan, J. Levels of retinyl palmitate and retinol in the stratum corneum, epidermis, and dermis of female SKH-1 mice topically treated with retinyl palmitate. *Toxicol. Ind. Health* 22: 181, 2006.
23. Sorg, O. Metabolism of topical retinaldehyde. *Dermatology* 199(Suppl. 1): 13, 1999.
24. Ito, Y. L. Liquid-gel partition chromatography of vitamin A compounds: Formation of retinoic acid from retinyl acetate in vivo. *J. Lipid Res.* 15: 517, 1974.
25. Sass, J. O. Metabolism of topical retinaldehyde and retinol by mouse skin in vivo: Predominant formation of retinyl esters and identification of 14-hydroxy-4, 14-retro-retinol. *Exp. Dermatol.* 5: 267, 1996.
26. MacKay, D. Nutritional support for wound healing. *Altern. Med. Rev.* 8: 359, 2003.
27. Baryza, M. J. The Vancouver Scar Scale: An administration tool and its interrater reliability. *J. Burn Care Rehabil.* 16: 535, 1995.
28. Sullivan, T. Rating the burn scar. *J. Burn Care Rehabil.* 11: 256, 1990.
29. Draaijers, J. The Patient and Observer Scar Assessment Scale: A reliable and feasible tool for scar evaluation. *Plast. Reconstr. Surg.* 113: 1960, 2004.
30. Bernard, F. X. Comparison of gene expression profiles in human keratinocyte mono-layer cultures, reconstituted epidermis and normal human skin: Transcriptional effects of retinoid treatments in reconstituted human epidermis. *Exp. Dermatol.* 11: 59, 2002.
31. Rosdahl, I. Vitamin A metabolism and mRNA expression of retinoid-binding protein and receptor genes in human epidermal melanocytes and melanoma cells. *Melanoma Res.* 7: 267, 1997.
32. Fisher, C. Retinoid receptors and keratinocytes. *Crit. Rev. Oral Biol. Med.* 6: 284, 1995.
33. Johnstone, C. C. The physiological basics of wound healing. *Nurs. Stand.* 19: 59, 2005.
34. Lynch, S. E. Growth factors in wound healing: Single and synergistic effects on partial thickness porcine skin wounds. *J. Clin. Invest.* 84: 640, 1989.
35. Tran, K. T. Extracellular matrix signaling through growth factor receptors during wound healing. *Wound Repair Regen.* 12: 262, 2004.
36. Ruzszzak, Z. Effect of collagen matrices on dermal wound healing. *Adv. Drug Deliv. Rev.* 55: 1595, 2003.
37. Faler, B. J. Transforming growth factor-beta and wound healing. *Perspect. Vasc. Surg. Endovasc. Ther.* 18: 55, 2006.
38. Martin, P. Inflammatory cells during wound repair: The good, the bad and the ugly. *Trends Cell Biol.* 15: 599, 2005.
39. Fenske, N. A. Structural and functional changes of normal aging skin. *J. Am. Acad. Dermatol.* 15: 571, 1986.
40. Tejero-Trujek, R. Understanding the final stages of wound contraction. *J. Wound Care* 10: 259, 2001.
41. Nusgens, B. V. Topically applied vitamin C enhances the mRNA level of collagens I and III, their processing enzymes and tissue inhibitor of matrix metalloproteinase 1 in the human dermis. *J. Invest. Dermatol.* 116: 853, 2001.
42. Palma, S. D. Potential use of ascorbic acid-based surfactants as skin penetration enhancers. *Drug Dev. Ind. Pharm.* 32: 821, 2006.
43. Falabella, A. F., and Falanga, V. Wound healing. In R. K. Feinkel and D. T. Woodley (Eds.), *The Biology of the Skin*. New York: Parthenon, 2000. Pp. 281–299.
44. Fenske, N. A. Structural and functional changes of normal aging skin. *J. Am. Acad. Dermatol.* 15: 571, 1986.
45. Ghyselinck, N. B. Genetic dissection of retinoic acid function in epidermis physiology. *Ann. Dermatol. Venereol.* 129: 793, 2002.
46. Chapellier, B. Physiological and retinoid-induced proliferations of epidermis basal keratinocytes are differently controlled. *E.M.B.O. J.* 21: 3402, 2002.